



PATIENT

Bam Bam Enright

SPECIES

Canine

BREED

Pitbull Mix

SEX

Male Neutered

AGE

14 years

WEIGHT

52lbs

INTERPRETED BY

Maggie Machen Lamy,
DVM, DACVIM
(Cardiology)

IMAGING PERFORMED BY

JK

HOSPITAL NAME

Hamburg Veterinary
Clinic

REFERRING VET

Dr. DenHeyer

INVOICE

24981

DATE

6/24/22

PRESENTING CLINICAL SIGNS

History: Recheck echo. Grade 2/6 heart murmur. Had syncopal event. BP: 178, 169, 164, 167mmHg.
-Current medications: Enalapril, Vetmedin.
-Pertinent previous echo findings (7/2019 EL): CVD B1, slight LAE.

ECHOCARDIOGRAM FINDINGS

2D, m-mode and doppler imaging is available. Mild diffuse thickening of mitral valve leaflets with no prolapse into the left atrial lumen. Minimal left atrial dilation. Normal LV diameter with adequate myocardial function. The tricuspid valve appears normal. Normal right atrial and ventricular diameter and morphology. The pulmonic and aortic valves are normal in morphology and mobility. Normal pulmonic and aortic outflow velocities with laminar flow. No pericardial or pleural effusion noted. No obvious cardiac masses.

CARDIAC CHART

CANINE CARDIAC PARAMETERS	MR VMAX (m/s)	TR VMAX (m/s)	LA/AO (Boon method)	LA/AO (Heart Base; Swe)	FS (%)	EF (%)	EPSS (cm)
NORMAL PARAMETER	4.5-5.5	<2.7	1.3	<1.6	28-40	40-100	<0.6
PATIENT	NM	NM	NM	1.4	37	70	NM
CANINE CARDIAC PARAMETERS	HR (BPM)	AV VMAX (m/s)	PV MAX (m/s)	BODY WEIGHT (kg)	LA 2D short axis Base view (cm)	LVIDd Avg; 2D and m-mode short axis (cm)	LVIDs Avg; 2D and m-mode short axis (cm)
NORMAL PARAMETER	50-100	0.7-1.7	0.7-1.6	BELOW	BELOW	BELOW	BELOW
PATIENT	220	1.4	0.8	23.6	2.4	3.8	2.4
*Normal chamber parameters expressed as a mean value (SD)				3	1.27 (5.3)	2.46 (2.46)	1.36 (5.5)
BODY WEIGHT DEPENDENT PARAMETERS				5	1.40 (4.5)	2.74 (5.2)	1.60 (4.7)
<i>*Note: All measurements based upon multi-modal images and methods. An average value is reported.</i>				10	1.50 (3.8)	3.27 (3.5)	2.06 (3.1)
				15	1.83 (2.0)	3.71 (2.4)	2.43 (2.1)
				20	2.02 (1.9)	4.14 (2.2)	2.80 (2.0)
				25	2.18 (2.4)	4.48 (2.9)	3.10 (2.5)
				30	2.33 (3.3)	4.83 (3.9)	3.39 (3.4)
				35	2.48 (4.3)	5.17 (5.0)	3.69 (4.5)
				40	2.62 (5.2)	5.48 (6.1)	3.96 (5.4)
				50	2.88 (7.1)	6.07 (8.3)	4.46 (7.4)

INTERPRETATION OF THE FINDINGS & FURTHER RECOMMENDATIONS

Overtly normal cardiac structure and function. Color flow is not utilized, and MR and TR are not ruled out. MR was seen previously, which is suspected to persist. Regardless, what is seen here does not show evidence of significant progression with normal left heart dimensions. Ancillary issues such as pulmonary hypertension are not ruled out in this study; however, the right heart is not overtly enlarged. No additional issues are clearly indicated. It is worth noting that this is not considered a complete study without use of color flow imaging. Further evaluation may be warranted; however, what is seen here does not appear hemodynamically significant.

Compared to what is available from the 2019 study there is no evidence of progression which is remarkable given the timeframe. The left heart dimensions have actually improved rather than



PATIENT

Bam Bam Enright

progressed. Pimobendan was recommended as a conservative approach previously; however, without chamber enlargement this is likely unnecessary. Additionally, unless Enalapril is being utilized for alternative reasons, there is no cardiac indication for it's use with mild disease.

SPECIES

Canine

These findings do not explain a syncopal event. Further historical information may be beneficial, such as situational component, etc. Additionally, a blood pressure and ECG should be obtained for a thorough evaluation. Prognosis is open prior to obtaining a complete study.

BREED

Pitbull Mix

No cardiac medications are indicated at this time. Monitor for any development of cough, labored breathing or exercise intolerance.

SEX

Male Neutered

PLAN

Consider discontinue Pimobendan and Enalapril as discussed. Further information regarding the event is necessary. Consider an ECG and BP and full echocardiogram. Referral should be considered if warranted.

AGE

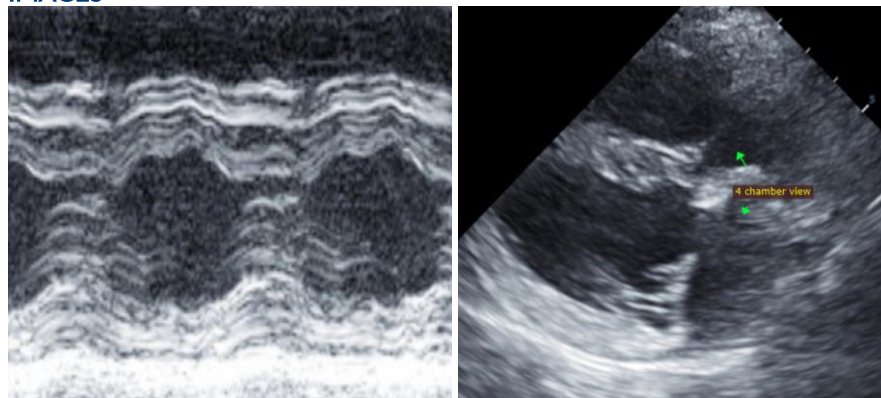
14 years

Recommend recheck echocardiogram pending the results of further evaluation.

WEIGHT

52lbs

IMAGES



INTERPRETED BY

Maggie Machen Lamy,
DVM, DACVIM
(Cardiology)

The information and recommendations provided are based on the images presented by the referring veterinarian. No evaluation can be communicated regarding pathology that was not visible in the image/video clips provided.

IMAGING PERFORMED BY

JK

HOSPITAL NAME

Hamburg Veterinary
Clinic

Thank you for this referral. This report was generated using transcription software, and minor dictation errors may be present. If the clinical or image interpretation does not parallel your findings or if I can be of any further assistance, please contact me.

REFERRING VET

Dr. DenHeyer

Maggie Machen Lamy, DVM
Diplomate of the American College of Veterinary Internal Medicine (Cardiology)
info@sonopath.com

INVOICE

24981

DATE

6/24/22